

# Effect of Biliary Stenting Combined With Ursodeoxycholic Acid and Terpene Treatment on Retained Common Bile Duct Stones in Elderly Patients: A Multicenter Study

Jimin Han, MD, PhD<sup>1</sup>, Jong Ho Moon, MD, PhD<sup>2</sup>, Hyun Cheol Koo, MD<sup>2</sup>, Jee Heon Kang, MD<sup>2</sup>, Joon Hyuck Choi, MD, PhD<sup>1</sup>, Seok Jeong, MD, PhD<sup>3</sup>, Don Haeng Lee, MD, PhD<sup>3</sup>, Moon Sung Lee, MD, PhD<sup>2</sup> and Ho Gak Kim, MD, PhD<sup>1</sup>

- OBJECTIVES:** For frail, elderly patients with large impacted common bile duct (CBD) stones, long-term treatment with biliary stenting provides palliation. Biliary stenting with choleric agents such as ursodeoxycholic acid (UDCA) and terpene preparations may promote CBD stone size reduction. We studied the effectiveness of biliary stenting combined with UDCA and a terpene preparation as a medical treatment for difficult-to-remove CBD stones in patients older than 65 years in this multicenter, prospective study.
- METHODS:** A total of 28 elderly patients with CBD stones refractory to conventional endoscopic removal, including mechanical lithotripsy, underwent endoscopic placement of a straight 10-F plastic biliary stent. Each patient was administered 600 mg of UDCA and 300 mg of a terpene preparation daily for a mean of 6 months. After 6 months of medication following the initial endoscopic retrograde cholangiopancreatography (ERCP), a second ERCP was performed and endoscopic stone removal was again attempted. Differences in stone size and CBD diameter before and after biliary stenting and medication were compared. The complete stone removal rate after treatment was obtained.
- RESULTS:** The mean size (transverse × longitudinal diameter) of the CBD stones was initially 21.6×29.5 mm, and it decreased significantly to 12.2×20.1 mm at the second ERCP ( $P<0.01$ ). The mean CBD diameter measured initially at the cystic duct insertion level was 23.2 mm, and it decreased significantly to 19.5 mm at the second ERCP ( $P<0.01$ ). After biliary stenting with medication, endoscopic stone removal was successful in 26 of 28 patients (92.8%), with a mean of 1.7 subsequent ERCP sessions.
- CONCLUSIONS:** Endoscopic biliary stenting with a period of combined UDCA and terpene preparation administration seems to be a safe and effective method for retained CBD stones in elderly patients. A prospective study with randomization and a control group is required to confirm these results.

*Am J Gastroenterol* advance online publication, 30 June 2009; doi:10.1038/ajg.2009.303

## INTRODUCTION

More than 80–90% of common bile duct (CBD) stones can be removed completely with endoscopic sphincterotomy followed by stone extraction (1). However, additional methods

are necessary for the removal of the remaining 10–20% of CBD stones that are difficult to extract (1–3). Of the various modalities, biliary stenting has an important role in the conservative management of CBD stones refractory to conventional

<sup>1</sup>Department of Internal Medicine, Catholic University of Daegu School of Medicine, Daegu, South Korea; <sup>2</sup>Department of Internal Medicine, Soon Chun Hyang University School of Medicine, Bucheon, South Korea; <sup>3</sup>Department of Internal Medicine, Inha University College of Medicine, Incheon, South Korea.

**Correspondence:** Jong Ho Moon, MD, PhD, Department of Internal Medicine, Soon Chun Hyang University School of Medicine, Digestive Disease Center, Soon Chun Hyang University Bucheon Hospital, 1174 Jung-Dong, Wonmi-Ku, Bucheon 420-767, Korea. E-mail: jhmoon@schbc.ac.kr

Received 19 February 2009; accepted 22 April 2009

endoscopic removal in elderly patients. The major aim of biliary stenting is the prevention of stone impaction at the ampulla and cholangitis, which is a life-threatening complication. However, whenever possible, a complete removal of difficult-to-extract CBD stones should be the final aim, even in elderly patients, because of complications associated with long-term biliary stenting.

After long-term treatment with biliary stenting for large CBD stones, stone fragmentation that enabled complete stone removal has been observed with variable, unsatisfactory success rates (2,4). Ursodeoxycholic acid (UDCA) is a hydrophilic dihydroxy bile acid that can dissolve gallstones (5,6). Combining oral UDCA with biliary stenting for the treatment of CBD stones that are difficult to remove can increase the rates of stone fragmentation and size reduction (5). A terpene preparation has been shown to enhance the solubility of cholesterol and also that of calcium carbonate and calcium phosphate, making it a potent choleric agent (7,8). The addition of both a terpene preparation and UDCA to biliary stenting may have a synergistic effect on facilitating the dissolution of bile duct stones (8–10). Therefore, we conducted a multicenter, prospective feasibility study to evaluate the effectiveness of biliary stenting combined with UDCA and a terpene preparation for difficult-to-remove CBD stones.

## METHODS

### Patients

From October 2005 to September 2008, 28 elderly patients over the age of 65 years and with difficult-to-remove CBD stones were enrolled. The patients presented with one or more of the following: biliary pain, jaundice, and fever. A difficult CBD stone was defined as a large and impacted CBD stone that was unable to be endoscopically removed, either by major endoscopic sphincterotomy or by mechanical lithotripsy. Extracorporeal or intracorporeal lithotripsy was not used for stone removal in this study. Exclusion criteria included the patient's or caregiver's refusal of treatment, a life expectancy of <6 months, and a history of side effects to UDCA and/or to a terpene preparation. The institutional review board at each participating hospital approved this study. Written informed consent was obtained from all of the enrolled patients.

### Procedures

Three endoscopic retrograde cholangiopancreatography (ERCP) endoscopists (J.H.M., D.H.L., and H.G.K.) with experience of more than 600 sessions of ERCP per year over the last 10 years were involved in this study, and each endoscopist interpreted the cholangiograms independently and consecutively. All the investigators participating in the study recorded the findings independently on a standardized data form. Cholangiograms were obtained after a full contrast injection, with the patient in the prone position and the duodenoscope in the shortened position. The initial CBD diameter and CBD stone size were measured from the cholangiogram obtained

during the initial ERCP by the same endoscopist who performed the ERCP. The CBD diameter was arbitrarily defined as the width of the CBD at the cystic duct insertion level, and the CBD stone size was defined as the maximum transverse diameter times the maximum longitudinal diameter. The CBD diameter and stone size were corrected for radiograph magnification by multiplying the ratio of the actual and measured diameters of the duodenoscope on the cholangiogram. The number of CBD stones was also recorded. After the attempted endoscopic removal failed, a single straight 10-F plastic biliary stent was placed, with the proximal end above the top of the difficult CBD stone. After the initial ERCP, each patient was administered daily medication consisting of 600 mg of UDCA (Ursa; Daewoong, Seoul, Korea) and 300 mg of a terpene preparation (Rowachol; Rowa Pharma, Cork, Ireland). The medications were continued for a mean of 6 months. The patients underwent regular follow-up every 4 weeks at an outpatient clinic, during which blood chemistry, simple abdominal X-rays, and compliance with the medication were checked.

After 6 months of medication, a second ERCP was performed by the same endoscopist who had performed the first ERCP. CBD diameter and CBD stone size and number were measured again using the same method and definitions, for comparison with the values at the initial ERCP. Endoscopic stone removal was attempted again using conventional endoscopic procedures, including mechanical lithotripsy.

### Statistical analysis

The results are expressed as means±s.d. To compare differences in variables between the initial and second ERCP, the Wilcoxon signed-rank test was used. SPSS for Windows ver. 11 (SPSS, Chicago, IL) was used to analyze the data, and  $P < 0.01$  was considered statistically significant.

## RESULTS

Of the 28 patients, 10 (35.7%) were men and 18 (64.3%) were women. The mean patient age was 74.5±6.2 (range: 65–88) years, and the mean number of CBD stones was 2.5±1.8 (range: 1–7).

Both the transverse and longitudinal diameters of the CBD stones decreased significantly after biliary stent placement and medication with UDCA and the terpene preparation (**Table 1**). In addition, the CBD diameter decreased significantly (**Table 1**). Stone size was reduced in 27 patients, remained unchanged in 1, and increased in none.

On follow-up ERCP, a spontaneous evacuation of the CBD stones was observed in one patient. Complete stone removal was achieved using only the basket and retrieval balloon catheter, without other additional procedures, in 16 (57.1%) patients (**Figure 1**). Ten patients (35.7%) required mechanical lithotripsy for complete stone removal. Thus, complete stone removal was achieved in 26 of 28 patients (92.8%) after biliary stenting with medication. The two patients with incomplete stone removal underwent long-term stent placement. The number of additional ERCP sessions required for complete stone removal was 1.7±0.8 (range: 1–3).

No immediate or late complications related to biliary stent placement or endoscopic stone removal were observed. Of the 28 patients enrolled in the study, there was no case of spontaneous dislocation of the biliary stent. No significant adverse side effects from the administration of either UDCA or the terpene preparation occurred, except for transient mild diarrhea in six patients.

## DISCUSSION

This study evaluated the effectiveness of biliary stenting combined with UDCA and a terpene preparation administered as a medical treatment for retained CBD stones. Complete stone removal was achieved in ~90% of the 28 elderly patients with difficult-to-extract CBD stones. Moreover, no significant complications related to biliary stent placement or medication occurred.

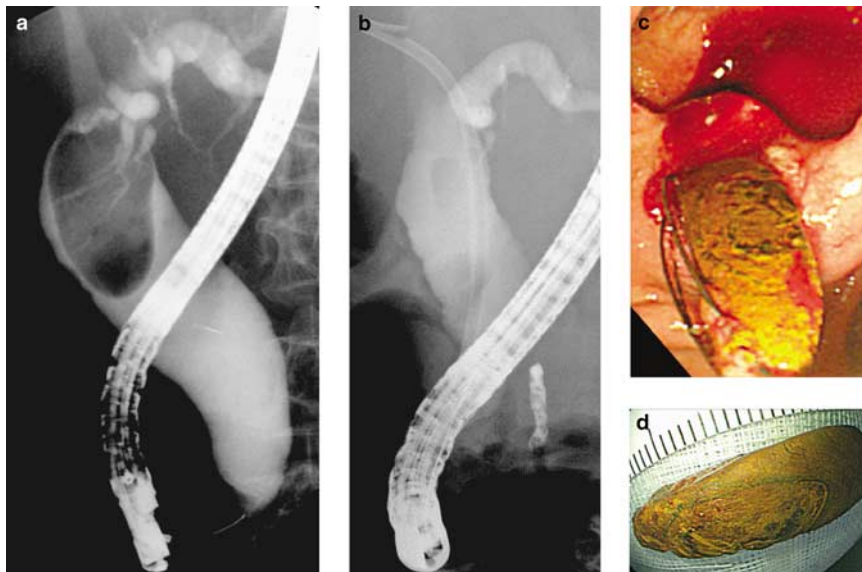
**Table 1.** Changes in CBD stone size and CBD diameter after biliary stent placement and medication with ursodeoxycholic acid and a terpene preparation in elderly patients

Parameter	Initial ERCP	Follow-up ERCP	P value
<i>CBD stone size (mm)</i>			
Transverse diameter	21.6±6.2	12.2±4.9	<0.01
Longitudinal diameter	29.5±14.3	20.1±1.2	<0.01
CBD diameter (mm)	23.2±6.1	19.5±3.8	<0.01

CBD, common bile duct; ERCP, endoscopic retrograde cholangiopancreatography.

Although more than 80–90% of CBD stones can be removed endoscopically, the remaining 10–20% are refractory to endoscopic removal, despite advanced lithotripsy methods (1). In elderly, frail patients who are poor candidates for surgery, biliary stenting has been used as a temporary, bridging measure to prevent stone impaction and acute cholangitis. Although biliary stenting provides immediate and successful drainage in 96% of cases, with a low early complication rate of 11%, the rate of long-term complications reached 40% in a group of 52 patients (11). Biliary stenting alone can reduce the size of CBD stones, but its effect on stone size is inconsistent, and the biliary stent must be exchanged in the case of occlusion or migration (2,4,10).

Both UDCA and terpene preparations have been used for their ability to dissolve gallstones (5,7). They have different mechanisms of action. UDCA, a hydrophilic dihydroxy bile acid (3 $\alpha$ ,7 $\beta$ -dihydroxy-5 $\beta$ -cholanoic acid), reduces the lithogenicity of bile by decreasing the biliary lipid output of cholesterol (6). In contrast, the terpene preparation is a well-tolerated oil preparation containing six cyclic monoterpenes; it inhibits hepatic hydroxymethyl glutaryl-coenzyme A reductase, alters biliary cholesterol saturation, can dissolve gallstones, and is more effective at low rather than at high dosages (12,13). It enhances the solubility of cholesterol as well as that of both calcium carbonate and calcium phosphate, making it a potent choleric agent (7). In normal healthy volunteers, a terpene preparation increased biliary cholesterol and phospholipid secretion, as well as bile acid secretion, but did not alter the composition of biliary lipids or the lithogenicity of bile. A terpene preparation alone has only weak litholytic properties, at least in normal volunteers. However, combining a terpene preparation with



**Figure 1.** Representation of a cholangiogram of a 74-year-old woman with a large common bile duct (CBD) stone who underwent successful endoscopic stone removal after biliary stenting and 6 months of ursodeoxycholic acid (UDCA) and terpene preparation administration. (a) The cholangiogram obtained at the initial endoscopic retrograde cholangiopancreatography shows a single, large, filling defect within the CBD. (b) After inserting a 10-F plastic biliary stent and treatment with UDCA and a terpene preparation for 6 months, the cholangiogram showed a significant decrease in the size of the stone. (c and d) Subsequently, the stone was removed successfully using only a Dormia basket.

UDCA may have several advantages, including the accelerated dissolution of gallstones (3,9), more effective reduction in bile lithogenicity (7), and a lower required dose of UDCA.

In a recent randomized, blinded trial on the combination of plastic biliary stents and oral UDCA of 750 mg or placebo for 6 months, there was no significant difference in CBD stone clearance (76.9 vs. 75%), stone size reduction ( $0.40 \pm 0.04$  vs.  $0.37 \pm 0.04$  cm), or number of patients with stone fragmentation (7 vs. 5) between the two groups (5). Few studies have examined the medical treatment of gallstones with a terpene preparation alone or in combination with bile acid derivatives (3,8). Complete or partial dissolution of gallstones was seen in 41% of cases after 6 months. In contrast, dissolution occurred in 15% of a terpene preparation-only group but in 0% of a chenodeoxycholic acid-only group (3). In patients with CBD stones, daily treatment with three capsules of a terpene preparation resulted in complete or partial stone dissolution in 46% of cases after 6 months and in 67% after 1 year (9). No major side effects related to the terpene preparation occurred. Therefore, the addition of UDCA and a terpene preparation to biliary stenting may have a synergistic effect on the fragmentation of retained CBD stones, thereby facilitating endoscopic removal at a later date.

As expected, the diameters of both the CBD and CBD stones decreased significantly after treatment with biliary stenting and the combination of UDCA and a terpene preparation in our study. Complete endoscopic stone removal was achieved in 92.8% of the patients, which is a higher rate than that reported in previous studies (4,5). Biliary stenting combined with UDCA and a terpene preparation was not only effective in the management of retained CBD stones but also safe. No serious complications related to either biliary stenting or treatment with UDCA and a terpene preparation were observed.

The limitations of this study are the small number of patients enrolled and the lack of a control group. Given that the success rate of endoscopic CBD stone removal exceeds 80–90% (1), enrolling a large number of patients with retained CBD stones was difficult, and the small number of patients with retained CBD stones made the recruitment of a control group unfeasible. On account of these limitations, it is difficult to be absolutely certain that the combination therapy was solely responsible for the benefits seen.

In conclusion, biliary stenting combined with the administration of UDCA and a terpene preparation seems to be a safe and effective method for treating difficult CBD stones in elderly patients. To validate these results, a randomized prospective study comparing the results of biliary stenting only, biliary stenting combined with UDCA, and a terpene preparation with respect to a control group is required.

#### ACKNOWLEDGMENTS

We thank Pharmbio Korea, Seoul, Korea.

#### CONFLICT OF INTEREST

**Guarantor of the article:** Jong Ho Moon, MD, PhD.

**Specific author contributions:** Study design, data analysis, and script preparation: Jong Ho Moon and Jimin Han;

endoscopic diagnosis and treatment: Jong Ho Moon, Don Haeng Lee, and Ho Gak Kim; data collection: Hyun Cheol Koo, Jee Heon Kang, Joon Hyuck Choi, and Seok Jeong; reviewers of the paper: Don Haeng Lee, Moon Sung Lee, and Ho Gak Kim. All authors have read and approved the submitted version of the paper.

**Financial support:** None.

**Potential competing interests:** None.

### Study highlights

#### WHAT IS CURRENT KNOWLEDGE

- ✓ Elaborate additional methods are necessary for the 10–20% of common bile duct (CBD) stones that are difficult to extract on endoscopic retrograde cholangiopancreatography. Biliary stenting has an important role in the conservative management of CBD stones in elderly patients, but it is not a definite treatment.

#### WHAT IS NEW HERE

- ✓ Biliary stenting combined with a period of treatment with ursodeoxycholic acid and a terpene preparation decreased the size of CBD stones, allowing successful endoscopic stone removal in 92.8% of elderly patients with difficult, retained CBD stones.

#### REFERENCES

- Hochberger J, Tex S, Maiss J *et al.* Management of difficult common bile duct stones. *Gastrointest Endosc Clin N Am* 2003;13:623–34.
- Katsinelos P, Galanis I, Pilpilidis I *et al.* The effect of indwelling endoprosthesis on stone size or fragmentation after long-term treatment with biliary stenting for large stones. *Surg Endosc* 2003;17:1552–5.
- Ellis WR, Bell GD, Middleton B *et al.* Adjunct to bile-acid treatment for gall-stone dissolution: low-dose chenodeoxycholic acid combined with a terpene preparation. *Br Med J (Clin Res Ed)* 1981;282:611–2.
- Kubota Y, Takaoka M, Fujimura K *et al.* Endoscopic endoprosthesis for large stones in the common bile duct. *Intern Med* 1994;33:597–601.
- Katsinelos P, Kountouras J, Paroutoglou G *et al.* Combination of endoprostheses and oral ursodeoxycholic acid or placebo in the treatment of difficult to extract common bile duct stones. *Dig Liver Dis* 2008;40:453–9.
- von Bergmann K, Epple-Gutsfeld M, Leiss O. Differences in the effects of chenodeoxycholic and ursodeoxycholic acid on biliary lipid secretion and bile acid synthesis in patients with gallstones. *Gastroenterology* 1984;87:136–43.
- Leiss O, von Bergmann K. Effect of rowachol on biliary lipid secretion and serum lipids in normal volunteers. *Gut* 1985;26:32–7.
- Ellis WR, Somerville KW, Whitten BH *et al.* Pilot study of combination treatment for gall stones with medium dose chenodeoxycholic acid and a terpene preparation. *Br Med J (Clin Res Ed)* 1989;289:153–156.
- Ellis WR, Bell GD. Treatment of biliary duct stones with a terpene preparation. *Br Med J (Clin Res Ed)* 1981;282:611.
- Soomers AJ, Nagengast FM, Yap SH. Endoscopic placement of biliary endoprostheses in patients with endoscopically unextractable common bile duct stones. A long-term follow up study of 26 patients. *Endoscopy* 1990;22:24–6.
- De Palma GD, Galloro G, Siciliano S *et al.* Endoscopic stenting for definitive treatment of irretrievable common bile duct calculi. A long-term follow-up study of 49 patients. *Hepatogastroenterology* 2001;48:56–8.
- Clegg RJ, Middleton B, Bell GD *et al.* Inhibition of hepatic cholesterol synthesis and S-3-hydroxy-3-methylglutaryl-CoA reductase by mono- and bicyclic monoterpenes administered in vivo. *Biochem Pharmacol* 1980;29:2125–7.
- Doran J, Keighley MR, Bell GD. Rowachol—a possible treatment for cholesterol gallstones. *Gut* 1979;20:312–7.